

NARMAYA THAPA

Department of ENT-Head Neck Surgery
Maharajgunj Medical Campus, Institute of
Medicine
Kathmandu, Nepal

Corresponding Author

Prof. Narmaya Thapa

Department of ENT-Head Neck Surgery
TU Teaching Hospital, Kathmandu, Nepal

Email:narmayat@gmail.com

EXTRACORPOREAL SEPTOPLASTY AND ITS MODIFICATIONS

ABSTRACT

Nasal septum plays an important role in the structure and function of the nose. If there is high septal deviation, it gives rise to crooked nose and /or deviation of tip, and it cannot be corrected by conventional septoplasty. Extracorporeal septoplasty and various types of modifications were developed to correct this kind of deformity.

Keywords : Conventional, Deviated nasal septum, Extracorporeal, Septoplasty

INTRODUCTION

Nose is the most prominent structure of face. It denotes facial beauty and racial identity. Nose is aesthetically divided into three parts-upper, middle and lower third. Upper third is bony part, while lower 2/3rd is cartilaginous (Fig.1). Deviation of the external nose from midline is called crooked nose. Crooked nose deformity can be due to deviation of either bony part or cartilaginous or both. Crooked nose is almost always associated with septal deviation. "As the septum goes, so goes the nose" is well-known phrase by famous rhinologist Maurice Cottle.¹ Along with external nasal deformity deviated nasal septum should be addressed to correct the external deformity and to get better aesthetic and functional results. Severe high and anterior deviation of cartilaginous part of septum cannot be corrected by classical septoplasty or septorhinoplasty. Extracorporeal septoplasty and its various modifications have been invented to correct curvatures of the mid and lower third of the dorsal septum.

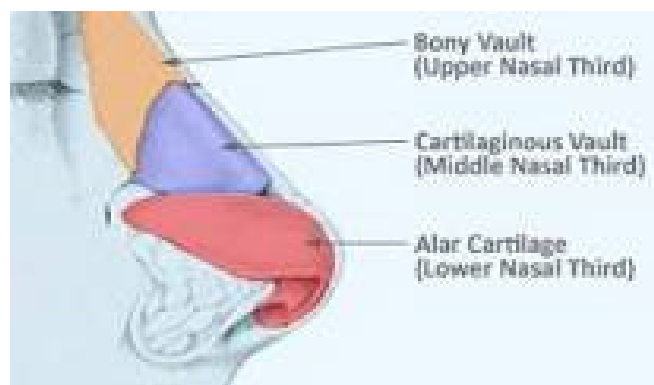


Figure 1: Parts of nasal dorsum

TECHNIQUES OF CORRECTION OF LOWER 2/3RD OF THE NASAL DORSUM

Complete removal and correction of nasal septum known as extracorporeal septoplasty

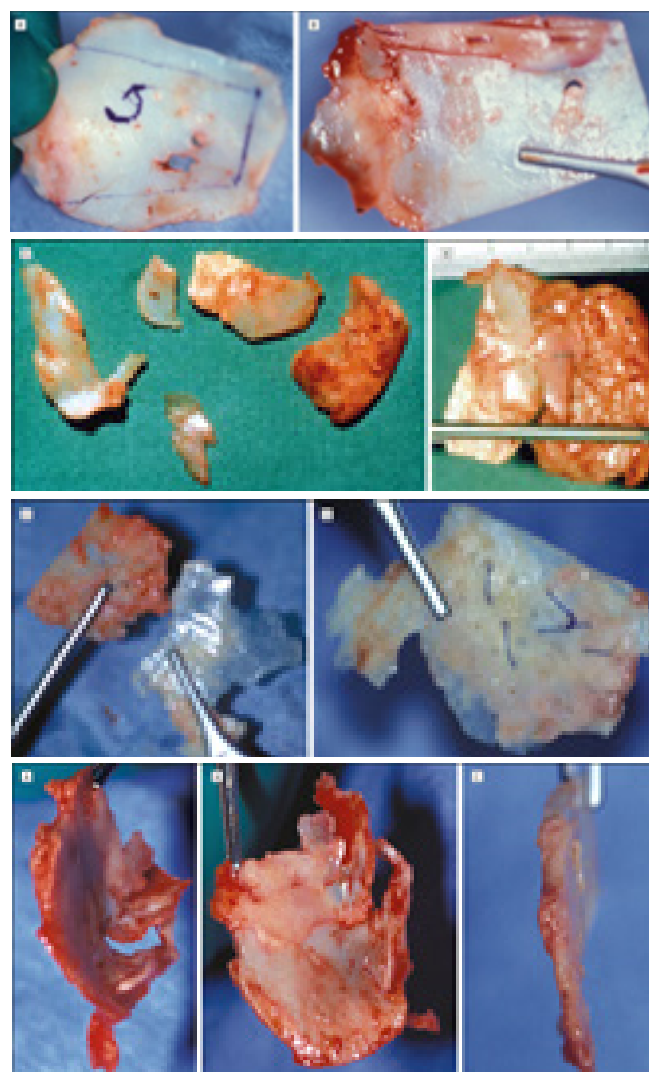

Figure 2: Various techniques of reconstruction of deviated septum (Gubisch technique)

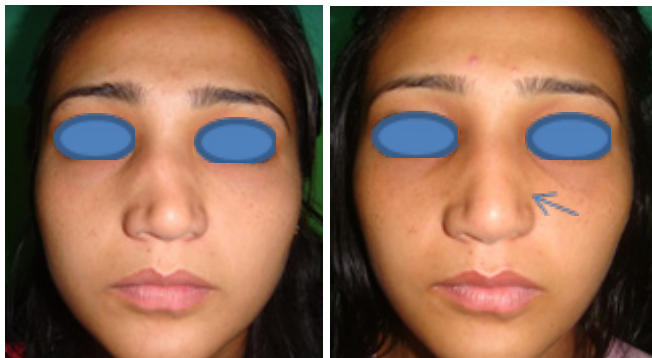


Figure III: 22 years lady with crooked nose preop (left) after classical extracorporeal septoplasty with inverted v deformity (right)

was suggested by King and Ashley in 1952, and Perret in early 1950s.^{2,3} However, extracorporeal septoplasty was first described and done by Professor Wolfgang Gubisch in the early 1980s. He performed complete removal of septal cartilage, sculpturing/reconstructing, reinsertion and fixation of the straightened cartilage to the anterior nasal spine and upper lateral cartilage (Fig.II).⁴ Gubisch et. al has described various ways of straightening the septum.⁵ However, total removal of septal cartilage and reinsertion was associated with aesthetic (inverted V deformity) in the keystone area as in (fig.III) Therefore in order to avoid this deformity various modifications have been evolved. Some of the popular techniques are described here.

MOST'S TECHNIQUE

The technique of extracorporeal septoplasty was first modified by Most, who emphasized maintaining a 1.0 to 1.5cm dorsal cartilaginous strut in the anteroposterior dimension. The crooked septum is resected and the septal remnant(s) explanted. Once the neoseptum has been reconstructed fashioning an "L-strut", the graft is placed onto the most concave aspect of the remaining dorsal strut or the side opposite the deviation. The preservation of this dorsal

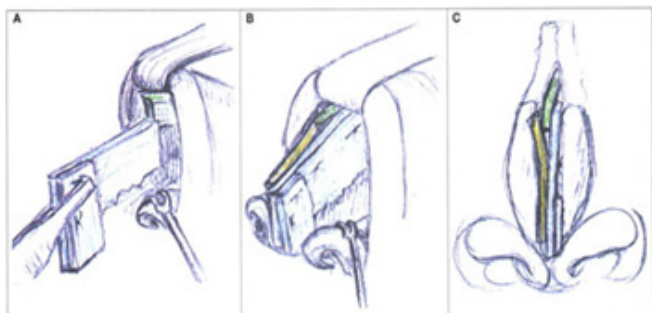


Figure IV: L-strut and spreader graft (Most technique)

strut at this "keystone" area allows the surgeon to secure the reconstructed septal L-strut to the native keystone cartilage. The graft is then sutured between the remaining dorsal strut and the upper lateral cartilage using 4-0 PDS. A spreader graft can be put in-between the upper lateral cartilage and the dorsal strut in cases of internal valve collapse (Fig.IV).⁶

BOCCIERI'S CROSSBAR TECHNIQUE

In severe deviations of septal cartilage use of septal crossbar grafts may be the appropriate method as described by Armando Bocchieri.

It is carried out by an open approach. Both the cartilaginous and the bony vaults of the nasal dorsum are carefully detached down to the subperichondrial and subperiosteal level. The two medial crura are drawn out and an incision is then made in the intercrural tissue to reach the most proximal part of the caudal septum. The next step is the subperichondrial detachment of both sides of the nasal septum. The dorsal portion of the nasal septum must be carefully separated extramucosally from the two upper lateral cartilages, using a Freer's elevator.

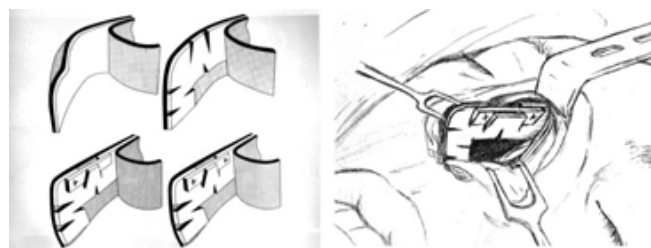


Figure V: Fixing crossbar (Bocchieri technique)

After complete exposure, all the deviated bony and cartilaginous septal sections can be removed, taking care to preserve an L strut at least 15 mm in width. Particular attention must then be given to harvesting the straightest possible strip of 3 to 6 mm in height and 1.5 to 2.5cm in length from the cartilaginous septum for subsequent implant in the dorsal septum as a crossbar graft.

In cases in which the cartilaginous septum has been removed in previous surgeries, a strip of the perpendicular plate of the ethmoid can be used for the same purpose. If the caudal base of the L strut appears off center with respect to the midline, it must be detached from the maxillary crest and the nasal spine and reattached in a central position with a polydioxanone (PDS) 4.0 suture.

Next step involves a series of incisions in both the

dorsal and the caudal pillar of the L strut. Another step is the positioning of the graft on the concave side of the dorsal septum or, in the case of linear deviation, on the side where a gap is present between the septum and upper lateral cartilages. As the crossbar graft is to be embedded between the two incisions in the dorsal pillar, it is useful to place the graft on the septum in that position before these are made. This makes it possible to determine the exact measurements of the two incisions in relation to the length of the graft and thus to leave a sufficient area of dorsal cartilage both in front and behind to which the crossbar graft is then secured with sutures.

Once lodged between the two vertical incisions in the dorsal septum, the crossbar graft is secured by means of two Vicryl 5.0 sutures. A third suture can also be applied a central position. In cases where an ethmoid crossbar graft is used, holes must be made in advance in the bone with a drill for the suturing thread. A continuous mattress suture is applied with Vicryl R 5.0 from front to back and from back to front to reattach the mucoperichondrium to the septum on both sides. Finally, the two upper lateral cartilages are sutured to the caudal most section of the nasal septum.⁷

MATT'S ET AL TECHNIQUE

In order to correct severely deviated caudal septum Matt et al. described a new technique.

The initial exposure of the septum is an external rhinoplasty approach in all cases. The domes are divided in the midline, and the upper lateral cartilages are released laterally, creating excellent exposure of the septum. Bilateral submucoperichondrial flaps are elevated, exposing the entire cartilaginous and anterior bony septum. The majority of the cartilaginous septum is then resected leaving dorsal remnant 1 cm or more but can vary from 1.5 cm down to as little as 0.8 cm in cases of severe high dorsal deviation.

The septum is then reconstructed on the back table. At this point it is determined whether additional cartilage is needed. If only a small amount of nonstructural supportive cartilage is required, conchal cartilage graft is obtained. If there is insufficient septal cartilage and more rigid or strong cartilage is needed for structural support, then a rib cartilage is used.

Now dorsal fixation is accomplished by placing the neocaudal septum on whichever side of the dorsal strut is most concave, as described by Most. When internal valve compromise has been diagnosed preoperatively, then additional spreader graft is placed.

Now the next step is caudal fixation. Sutures with 6-0 PDS are placed through the vestibular epithelium of the medial crus, the neocaudal septum, and the contralateral medial crural vestibular skin and then back through all 3 structures to complete a mattress stitch.

Final reconstruction is often done by placing small patties (2-5 mm in diameter) of crushed cartilage around the posterior septal angle of the neocaudal septum where it is in close contact with the nasal spine, but no suturing to the nasal spine is needed.

Before closing the incision, plastic splints are placed along either side of the septum. The inferior and anterior edge of each splint is cut to fit securely along the floor of the nose and just alongside or slightly posterior to the medial crura cartilages. The splints are sutured into place with through-and-through 4-0 black nylon suture. One or 2 sutures are placed low on the splints. This tends to pull everything into the midline. Then 1 or 2 sutures are placed caudally, just behind the medial crura, for further caudal fixation. One or 2 additional sutures may be placed in the upper to middle body of the neocaudal septum to increase midline fixation and stability.⁸

TORIUMI'S TECHNIQUE

Prof. Dean M. Toriumi described a subtotal septal reconstruction as a surgical technique for severe septal deviations that are not easily repaired using less invasive methods. Patients with identifiable septal fractures across the caudal or dorsal segments of the L-strut are good candidates for this technique.

This technique is performed via the external rhinoplasty approach. Then dissection is done between the medial crura, exposing the caudal septum. elevating Bilateral mucoperichondrial flaps are elevated, and then the upper lateral cartilages are freed from the dorsal nasal septum. It is advisable to leave at least 1.5 cm of septal cartilage attached at the perpendicular plate of the ethmoid bone to make sure there is

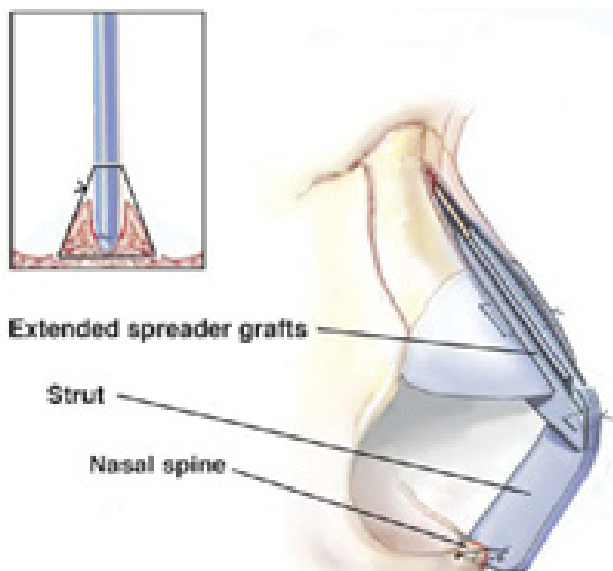


Figure VI: Fixing bilateral extended spreader grafts and columellar strut(Toruimi technique)

no disruption of the dorsal strut at the keystone area. According to Prof. Toriumi this maneuver provides maximal exposure of the caudal and dorsal septum. Adequate exposure of the dorsal septum is necessary to allow proper stabilization.

Adequate autologous cartilage is needed to reconstruct the septum. The deviated segments of the nasal septum are removed and then reconstructed by replacing the caudal septum with a straight piece of septal cartilage fixated to the nasal spine. The bilateral extended spreader grafts are fixed to the remnant dorsal strut and then fixed to the caudal septal replacement graft to reconstitute the L-strut. In some cases, the dorsal strut may overlap the caudal portion of the L-strut to complete the repair. Care must be taken in setting nasal length, projection, rotation, and supratip break.⁹

SUROWTZ ET AL TECHNIQUE

Anterior septal reconstruction represents a powerful method for correction of nasal valve stenosis resulting from severe antero-caudal

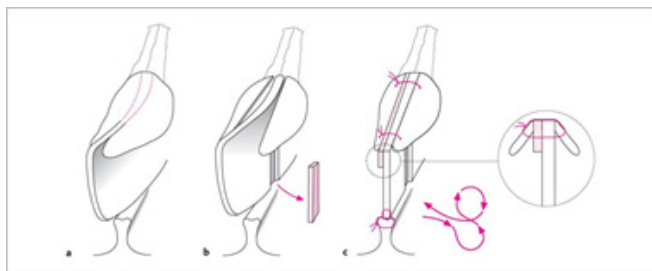


Figure VII: Resecting the inferior portion of septal cartilage and fixing as an unilateral spreader graft.

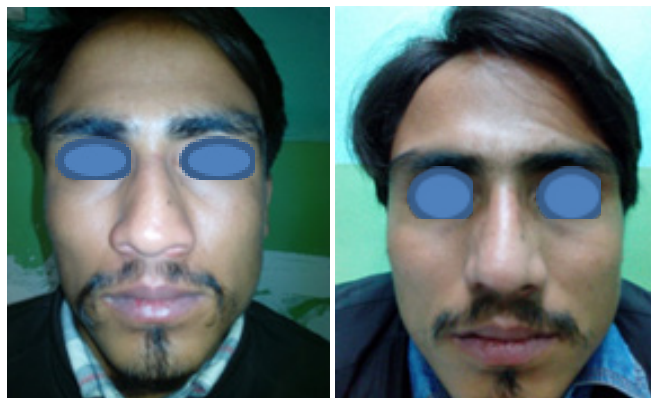

Figure VIII: 30 years old male with crooked nose before surgery(left) after extracorporeal septoplasty with unilateral spreader graft (right).

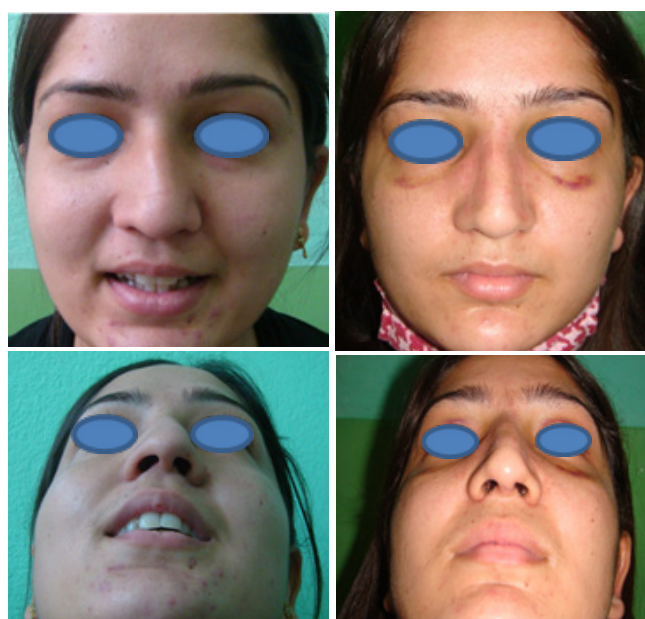

Figure IX: 25 year old female with crooked nose (left) and after modified extracorporeal septoplasty with bilateral spreader grafts (right).

septal deviations. This reconstruction is also done by open approach. After subperichondral and subperiosteal flap elevation resection of inferior part of the deviated septal cartilage is done. This septal cartilage is used as unilateral spreader graft and fixed on the concave side. The posterior septal angle is fixed with anterior nasal spine as shown in the figure (Fig.VII).¹⁰

CONCLUSION

After demonstration of classical extracorporeal septoplasty by Gubisch, several technical options have been described by different authors for creating a straight septal plate. Whichever technique is used there should be functional as well as aesthetic correction of the nose.

REFERENCES

1. Barelli PA, Loch WE, Kern EB, Steiner A. Rhinology: the collected writings of Maurice H. Cottle, MD Rochester, MN. American Rhinologic Society. 1987;11(4):191–92.
2. King ED, Ashley FL. The correction of the internally and externally deviated nose. *Plast Reconstr Surg.* 1952;10:116-120.
3. Perret P. Correction chirurgicale des nez devies. *Pract Otorhinolaryngol (Basel).* 1958;20:115-124.
4. Gubisch W. Extracorporeal septoplasty for the markedly deviated septum. *Arch Facial Plast Surg.* 2005; 7 (4):218-226.
5. Gubisch W, Sinha V. Extracorporeal septoplasty-how we do it at Marien hospital Stuttgart Germany. *Indian J Otolaryngol Head Neck Surg.* 2008;60 (1):16-19.
6. Most SP. Anterior septal reconstruction: outcomes after a modified extracorporeal septoplasty technique. *Arch Facial Plast Surg.* 2006; 8 (3):202-207.
7. Boccieri A. Evolution of the septal crossbar graft technique. *Facial Plast Surg,* 2006; 22 (4):255-265.
8. Matt A, Wilson MA, Mobley SR. Extracorporeal septoplasty: complications and new techniques. *Arch Facial Plast Surg.* 2011; 13 (2):85-90.
9. Toriumi DM. Subtotal Septal Reconstruction. *Facial Plast Surg* 2013; 29(06): 492-501.
10. Surowitz J, Lee MK, Most SP. Anterior Septal Reconstruction for Treatment of Severe Caudal Septal Deviaiton: Clinical Severity and Outcomes. *Otolaryngol Head Neck Surg.* 2015 Jul;153(1):27-33.

